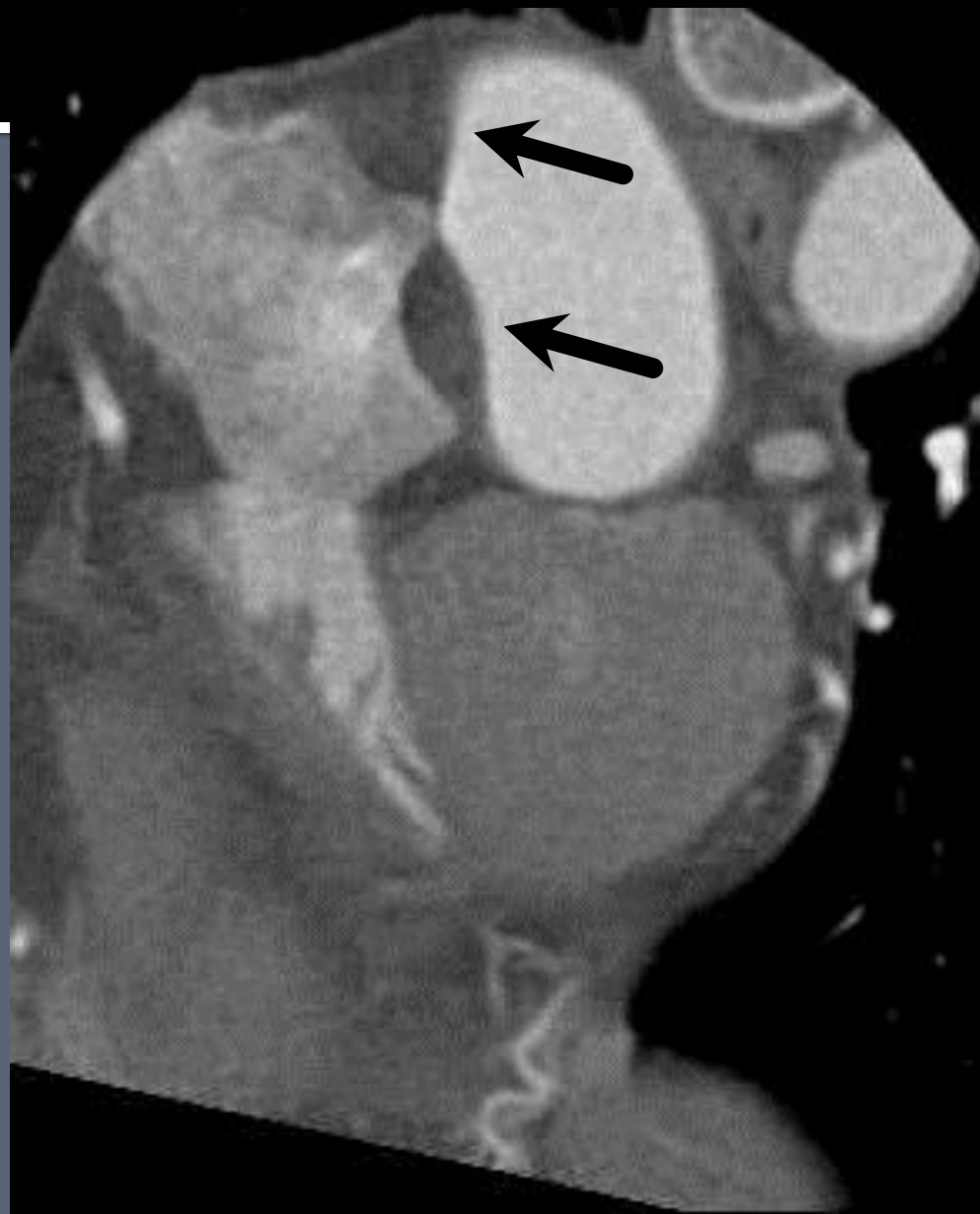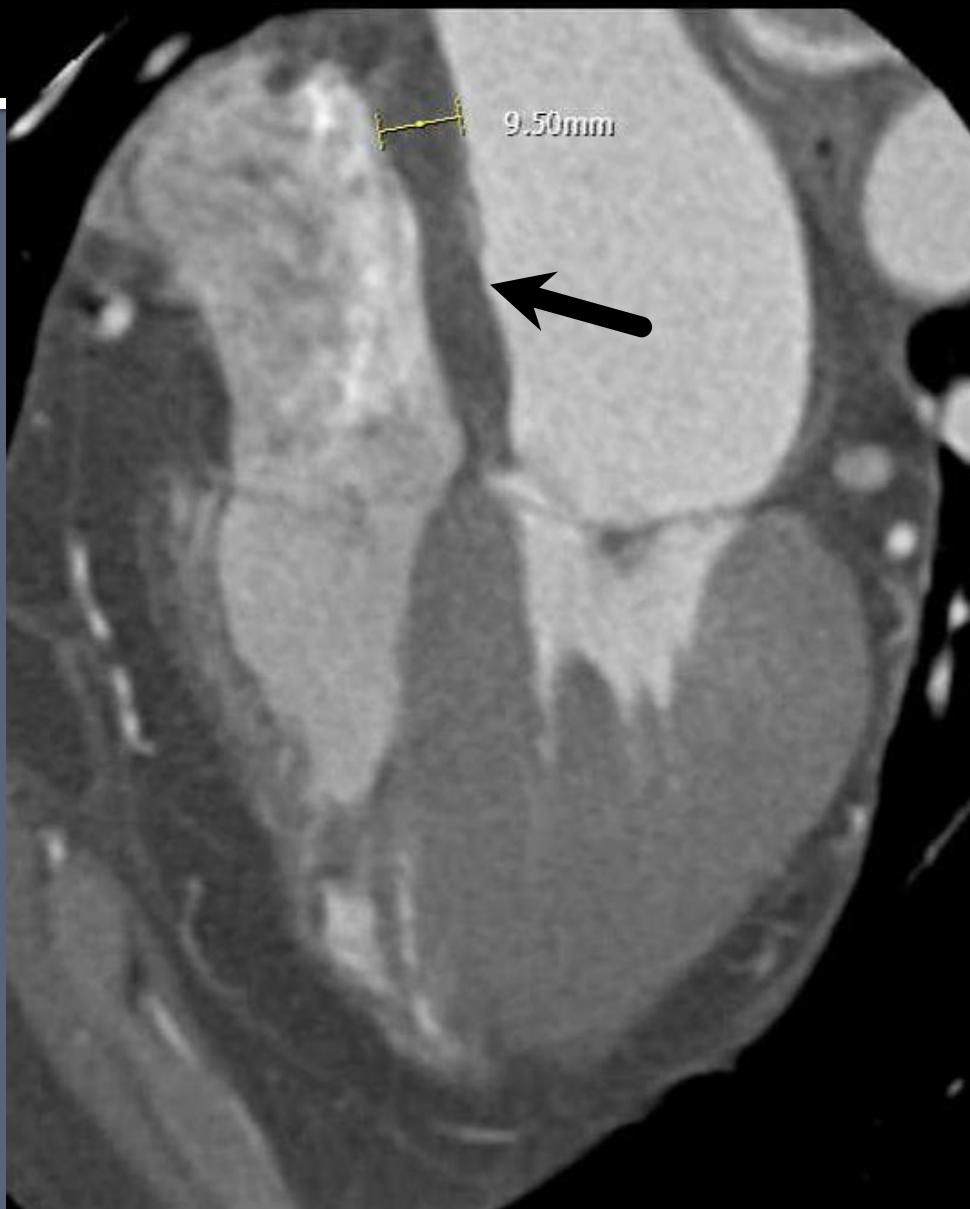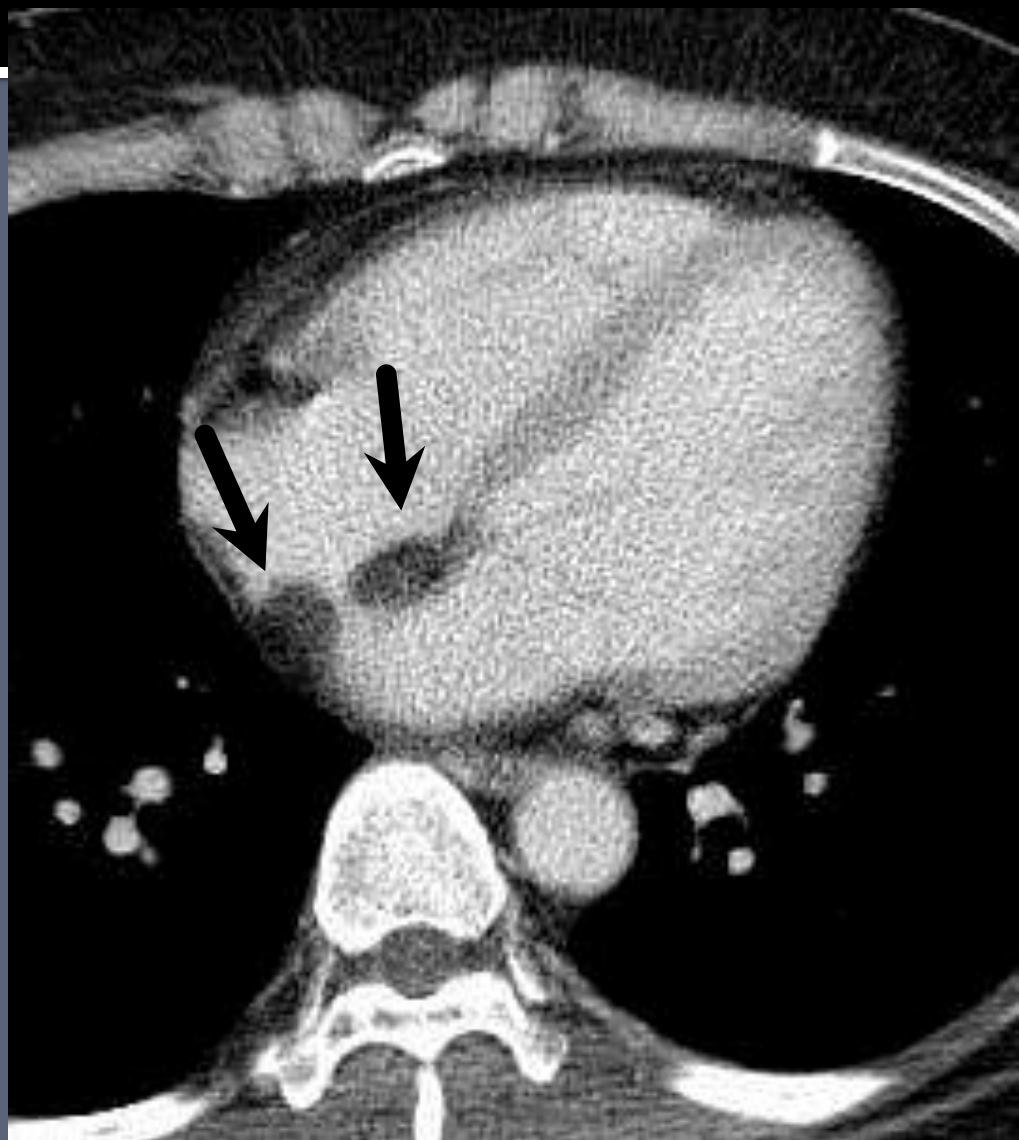
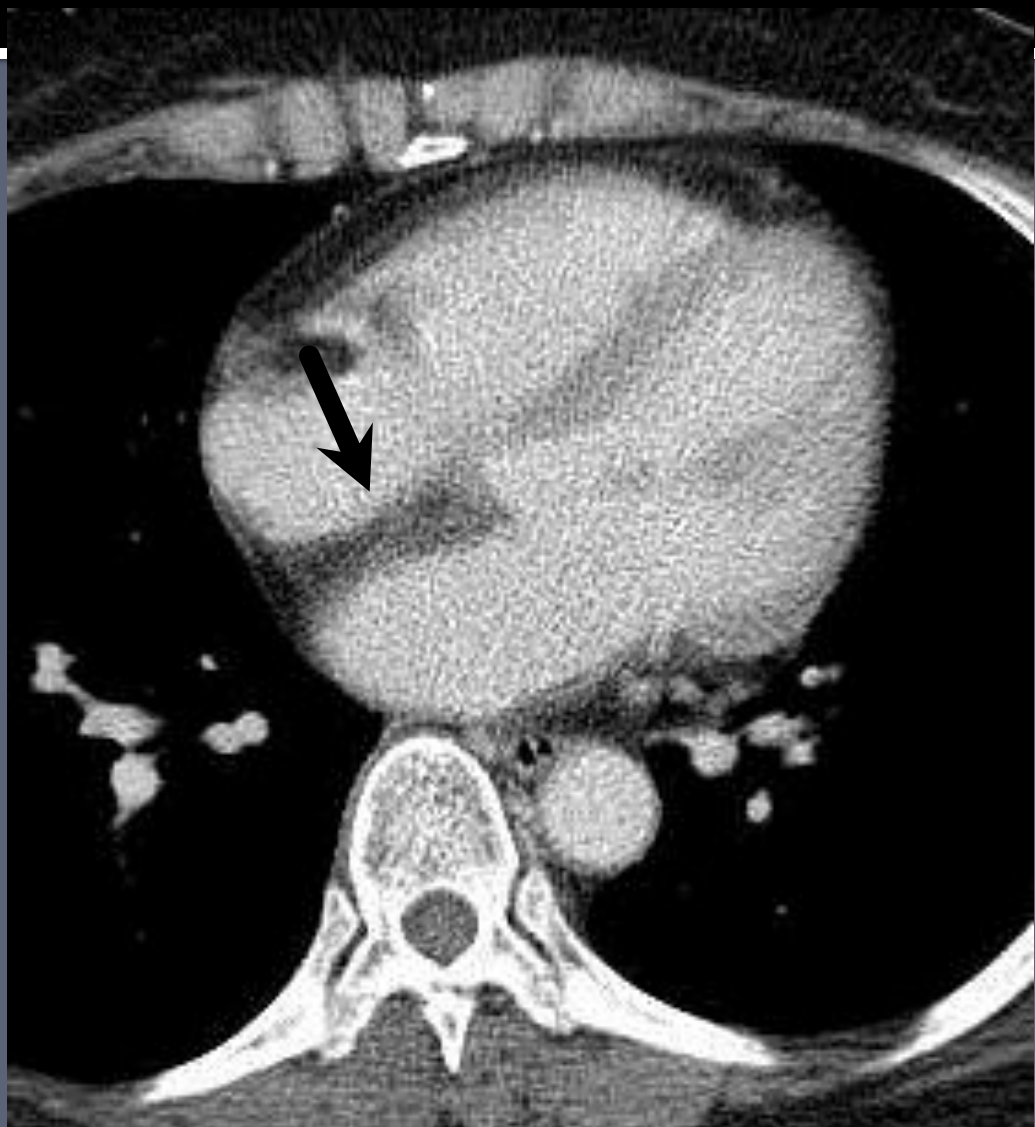


# **Case : 50yr / F**

- **C.C: Atypical chest pain (onset; 6 MA)  
chronic cough**





# **Radiologic findings**

- **Focal fat accumulation at interatrial septum (maximum thickness; 1cm) with sparing of fossa ovalis**

# Lipomatous hypertrophy of the interatrial septum

- benign condition of fat accumulation in the interatrial septum.
- Uncapsulated mass that can contain adipocyte, myocyte and fibrosis.
- Adipose cell hyperplasia (age, obesity related)
- No intercavitary or extracardiac component (vs lipoma)
- Asymptomatic, but associated with atrial arrhythmia, P wave alteration, and SCD
- CT : non-enhancing, well margined fat containing mass **characteristic dumbbell shape with sparing of fossa ovalis.**
- DDx : myxoma, rhabdomyoma, fibroma, fibroelastoma